Academy of Osseointegration
osseo.org

Academy NEWS

A QUARTERLY MEMBER NEWSLETTER

Back to the Future of Osseointegration

VOLUME 33, NUMBER 1 • 2022

Guided Surgery Solutions

Your path to predictable implant therapy

Zimmer Biomet Dental's Guided Surgery Solutions provide seamless and flexible workflow solutions that will guide you through dental implant therapy. They consist of the RealGUIDE™ Software Suite and compact guided surgery toolkits for most Zimmer Biomet implant systems. Trained virtual planners are available to do your treatment planning and guide design on demand through guided surgery services branded as Implant Concierge™.

Irrespective of which option you choose, Zimmer Biomet Dental provides you with tools and services aimed at providing secure, minimally invasive, guided implant therapy.*

2022 ANNUAL MEETING
IMPLANT DENTISTRY FOR ALL:
HONORING The Past
TREASURING The Present
SHAPING The Future
Feb. 24–26 San Diego, CA

Learn more, visit Booth #900

Find your solution today, simply scan the code or visit zbdguidedsurgery.com

RealGUIDE™ UNIVERSAL OPEN SYSTEM | implant concierge™

*References: Accuracy of Edentulous Computer-Aided Implant Surgery as Compared to Virtual Planning: A Retrospective Multicenter Study; R. Vinci, M. Manacorda, R. Abundo, A. G. Lucchina, A. Scarano, C. Crocetta, L. Lo Muzio, E. F. Gherlone, F. Mastrangelo; J Clin Med. 2020 Mar 12;9(3):774. doi: 10.3390/jcm9030774 // Clinical Factors Affecting the Accuracy of Guided Implant Surgery - A Systematic Review and Meta-analysis; Wenjuan Zhou, Zhonghao Liu, Liansheng Song, Chia-Ling Kuo, David M Shafer; pubmed.gov; Epub 2017 Jul 22

FDA 510(k) number: K173041
Owner number: 10059505

TABLE OF CONTENTS

IN THIS ISSUE

ACADEMY **NEWS**
Academy of Osseointegration
85 W. Algonquin Road, Suite 550
Arlington Heights, IL 60005
847.439.1919

President's Message

Honoring the Past

By Tara L. Aghaloo, DDS, MD, PhD

It's hard to believe this edition of *Academy News* includes my final column. That might sound a little trite as something every other president has said. It really has been such an honor and privilege to serve this esteemed Academy for 11 years, leading up to my role as the 35th and second female president, and the first to ascend from serving two full terms as a director through all of the chairs.

Let me start out by saying it would be impossible to fully honor our history in this limited space. However, here is my genuine attempt to recognize some of the Academy's numerous milestones.

The past few years have been unprecedented due to the pandemic, with much of the board's time laser-focused on keeping the Academy running strong. The decision to cancel our 2020 Annual Meeting in Seattle seemed to be heart-wrenching at the time. Just days before it was scheduled to begin, a special board meeting was called by Dr. **Jay P. Malmquist** to fully understand and discuss the impact of that decision. It was absolutely the correct one, and as it turns out, the Academy was one of the very first organizations recognized to cancel a major meeting on the cusp of the pandemic. During his term, Dr. Malmquist also brought forward the *International Journal of Periodontics & Restorative Dentistry* as a new membership benefit, making it the Academy's second official journal.

Following up to that was the Academy's first-ever virtual Annual Meeting in 2021 under the leadership of my predecessor, Dr. **Clark M. Stanford**. A new Academy-centric online discussion platform, the AO DocMatter Community, also debuted as a major benefit of membership during his term.

Coming through this pandemic, I am extremely grateful how the Academy has flourished in ways we could not have imagined. This includes launching the Academy's new AO Master and AO Diplomate credentialing program, thanks to Academy Vice President Dr. **Hom-Lay Wang**, who spearheaded this major initiative.

Going back to our earliest days, our inaugural president, Dr. **William R. Laney**, adopted the *International Journal of Oral & Maxillofacial Implants* as the Academy's official journal in 1987, and presided over our very first Annual Meeting in Chicago in 1986. Trailblazer and first female president of the Academy, Dr. **Marjorie K. Jeffcoat**, organized the State of the Science on Implant Dentistry in 2006 during our 20th anniversary, as well as initiatives to provide implant dentistry education at all levels, especially with students.

The Academy also organized a Sinus Lift Conference, the first of its kind in implant dentistry during the presidency of Dr. **Edwin S. Rosenberg** in 1996, having been spearheaded in 1995 by president Dr. **Michael S. Block**. These meetings would pave the way for AO Summits, now held every four years, beginning in 2010 in conjunction with our 25th Anniversary, during the presidency of Dr. **Vince J. Iocono**.

After being established in 1991, there was a push to make the Osseointegration Foundation, the Academy's philanthropic arm, self-sustaining. With the establishment of OF's Titanium Society led by 15th President Dr. **Dayn C. Boitet** and continued financial support of dentists from around the world, the Foundation proudly celebrated its 30th anniversary last year.

Another landmark moment occurred in 2003 during the term of Dr. **James H. Doundoulakis**, who led the effort to hold the first collaborative Annual Meeting, uniting the Academy with three specialty dental organizations. It continues to be the largest attended Annual Meeting in our history.

One of my most memorable AO Annual Meetings was 2011 in Washington D.C. under Dr. **Peter K. Moy**, which remains the largest attended stand-alone Academy meeting. This was also unforgettable to me serving as the program chair that year, which included richly historical and classy social events.

By 2013, during the term of Dr. **Stephen L. Wheeler**, the Academy held a meeting of its second Charter Chapter. Robust global outreach would continue to be a strategic initiative during the terms of our five subsequent Presidents, with several Charter Chapters formed and meetings among key opinion leaders held across four continents, as well as translation services offered at our Annual Meetings.

And we certainly cannot leave out why we are in existence – Swedish researcher Prof. **Per-Ingvar Brånemark** – widely considered as the father of osseointegration, and our

Continues on page 5

Nominations for AO board include new director, treasurer

Dr. Robert Levine

Dr. Joseph Fiorellini

Nominated for election to the Academy of Osseointegration (AO) Board of Directors at the Annual Business Meeting February 26, 2022 in San Diego, CA, will be AO Fellow **Robert A. Levine**, DDS, a periodontist in private practice from Philadelphia, PA. Nominated for election as treasurer will be current director and AO Fellow **Joseph P. Fiorellini**, DMD, DMSc, Chair of the Department of Periodontics at the University of Pennsylvania School of Dental Medicine.

Dr. Levine maintains a private practice in Philadelphia at the Pennsylvania Center for Dental Implants and Periodontics. He graduated from Temple University School of Dentistry in 1981, received his post-grad certificate in periodontics from the University of Pennsylvania in 1984. He is presently a clinical professor in Post-Graduate Periodontics and Dental Implantology at Temple University, a clinical assistant professor at the University of North Carolina, and an adjunct clinical assistant professor at the University of Illinois College of Dentistry.

Active in the Academy and a member since its inception in 1985, Dr. Levine most recently served on the Research Submission Committee. He has also been active on the Academy's Clinical Innovations, ePoster, and 2018 Annual Meeting committees. He has authored close to 90 publications. His wife, Sheryl, and two children, Ross and Bari, who are pediatric dentists, run the Growing Smiles Foundation, a non-profit dental organization which has treated children and adults in low-income areas in Lima, Peru.

"It is truly an honor to be appointed to the AO Board of Directors. I was present at the first organized meeting in implantology in Chicago more than 35 years ago as a young practicing periodontist. With our Academy's history in mind and those who walked before us, I am now able to give back to our organization. AO has made such an impact in my professional and personal life since that first meeting. I have been very fortunate in developing many long-term friendships because of being an active member."

AO members participating in the annual business meeting will elect a new slate of officers headed by AO Fellow **Amerian D. Sones**, DMD, MS, president; AO Fellow **Hom-Lay Wang**, DDS, MSD, PhD, president-elect; AO Fellow **Joerg Neugebauer**, DDS, PhD, vice president; AO Fellow **Robert C. Vogel**, DDS, secretary; and AO Fellow **Joseph P. Fiorellini**, DMD, DMSc, treasurer. Continuing on the board are AO Fellow **Tara L. Aghaloo**, DDS, MD, PhD, immediate past president; and directors AO Fellow **Jeffrey Ganeles**, DMD; Stephen L. Jacobs, BDS; AO Fellow **Joseph Y K Kan**, DDS, MS; **Robert R. Lemke**, DDS, MD; AO Fellow **Robert A. Levine**, DDS; and AO Fellow **Lambert J. Stumpel,** DDS.

President's Message *(continued from page 4)*

collaborations with him before the Academy was officially established. A two-day symposium in Toronto in 1982 facilitated by **George A. Zarb** led to four U.S. training centers that Prof. Brånemark needed to spread the word about his discovery to dentists in North America. That motivated Dr. **Charles L. Berman** (who went on to become our fifth president), and other founding members to organize dentists into a local study club in metro New York to discuss Prof. Brånemark's techniques. This group subsequently mobilized into the global Academy we know and love today. Prof. Brånemark, the first Honorary AO Fellow, continued to attend and speak at our Annual Meetings until his passing in 2014.

What are some of your favorite moments in the Academy's history? Email Editor Dr. **Mehrdad Favagehi** at mfavagehi@yahoo.com and let us know!

THANK YOU to all of the industry icons, visionaries and trailblazers who served as Academy president before me and has made it what it is today: Drs. the late **William R. Laney**, the late **Paul H.J. Krogh**, **Gerald Barrack**, the late **Irving B. Stern**, the late **Charles L. Berman**, the late **Daniel Y. Sullivan**, the late **Thomas A, Collins**, **Stephen M. Parel**, **Michael S. Block**, **Edwin S. Rosenberg**, **Gerald N. Graser**, the late **Bejan Iranpour**, the late **Abraham Ingber**, **Melvyn S. Schwarz**, **Dayn C. Boitet**, **James H. Doundoulakis**, **Clarence C. Lindquist**, the late **Marjorie K. Jeffcoat**, **Richard K. Rounsavelle**, **Edward B. Sevetz, Jr.**, **Steven G. Lewis**, **Vincent J. Iacono**, **Peter K. Moy**, **Kenneth F. Hinds**, **David L. Cochran**, **Stephen L. Wheeler**, **Joseph E. Gian-Grasso**, **Russel D. Nishimura**, **Alan S. Pollack**, **Michael R. Norton**, **James C. Taylor**, **Jay P. Malmquist**, and **Clark M. Stanford**.

This final column is not to say "goodbye," but instead, "see you around." Hopefully in San Diego! I look forward to passing the baton to AO Fellow and our next female President, Dr. **Amerian D. Sones**. It has been an honor and pleasure to work with this board and staff. I am grateful for their support and to you for your continued membership in the Academy.

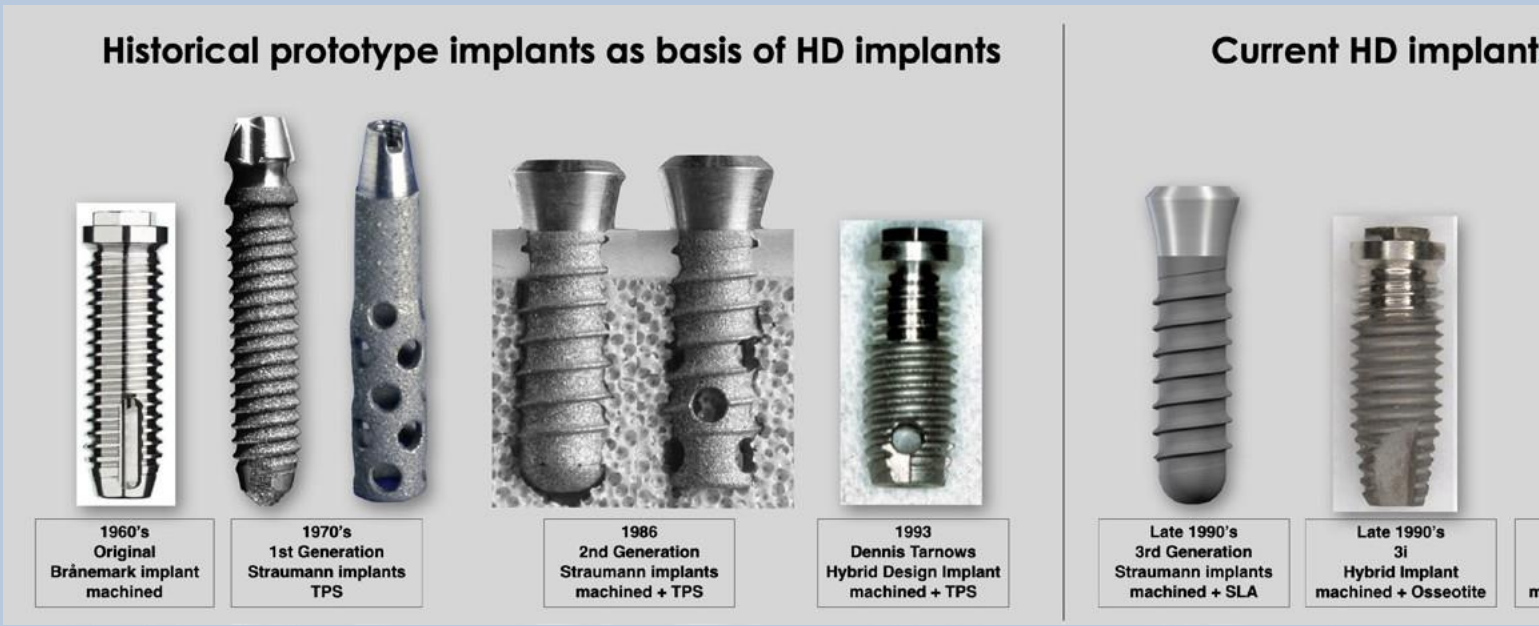

Fig. 1: This shows on the left the prototype implants which lead to the development of HD implants. On the right side, you see current HD implants, whi

Hybrid Design Implants: Is this the future in implan

By Daniel Buser, DMD, Dr. med.dent., Professor emeritus, University of Bern, Academy News *Guest Contributor*

Dental implant surfaces have been a hot topic in the mid 1990s, when a paradigm shift from the machined to micro-rough implant surfaces took place (Buser et al., 2017).

The original implants tested by Prof. **Per-Ingvar Brånemark** at the University of Gothenburg in the late 1960s (Fig. 1), had a smooth, machined surface. The clinical examination showed several short comings, such as long healing periods, increased early failure rates, increased late failure rates in the maxilla, and the need for rather long implants up to 18 mm of length. On the other hand, these implants had a very low prevalence of peri-implant infections.

The second implant surface in the mid 1970s was the TPS surface used for the first generation Straumann implants and tested by the group around Prof. **André Schroeder** at the University of Bern. This was a rather rough, coated implant surface. These implants showed excellent osseointegration in preclinical and clinical studies, but also a new form of peri-implant infection, called peri-implantitis, which was first described by Mombelli et al. (1987). It was obvious that the rough TPS surface, being present in the transmucosal part of these one-piece implants, was a causative factor for the observed infections.

In 1986, the second-generation Straumann implants were two-piece implants with two implant surfaces, later called *Tissue Level* implants, with the TPS surface in the endosseous portion for optimal bone anchorage, and a machined surface in the neck area for the supracrestal, transmucosal portion. In 1993, **Dennis P. Tarnow** also proposed to use both implant surfaces to benefit from the synergistic characteristics of both surfaces and created the new term *Hybrid Design (HD)* implant (Tarnow 1993).

In the late 1990s, several micro-rough implant surfaces were introduced to the dental market produced by sandblasting and acid-etching, or acid-etching alone, such as the SLA®, Osseotite®, and Osseospeed® implant surface. The main arguments were a better and faster bone integration allowing shorter healing periods and shorter implants, reduced early failure rates, and the same success rates in both jaws.

Heated debates followed at implant congresses, and prominent speakers of the Brånemark group strongly argued that these micro-rough implant surfaces would cause a high prevalence of peri-implantitis. Despite this warning, all implant companies made a paradigm shift



ch are on the market.

t dentistry?

within a few years, and today, all relevant implant systems sold on the market have a micro-rough implant surface for improved bone anchorage.

In the past 20 years, implant therapy has seen a wide expansion, and today more than 30 million dental implants are yearly inserted around the globe. Several hot topics have been debated at implant congresses such as implant esthetics, the timing of implant placement, the timing of implant restauration/loading, and digital implant dentistry. In these areas, implant therapy made a tremendous progress for the benefit of our patients.

Another hot topic has been, and still is, peri-implantitis, which is a negative issue since it deals with a potentially severe complication of implant therapy. For more than 25 years, peri-implantitis has been discussed at consensus conferences, and analyzed with countless systematic reviews and position papers. Depending on defined criteria, the prevalence of peri-implantitis seems to be between 10 and 50%, a major problem from a public health point of view.

Many risk factors for the development of peri-implantitis have been discussed, such as a history of periodontal disease, poor oral hygiene, smoking, the lack of keratinized mucosa, medical diseases such as diabetes and so on. One factor has been overlooked for years: the implant surface in the transcrestal area of the implant shoulder.

Today, I am convinced, that a micro-rough implant surface exposed to the peri-implant sulcus is an important risk factor for the development of peri-implantitis, in particular when it is combined with other co-factors. When an implant has a micro-rough implant surface at the crestal bone, the likelihood to get exposed during initial bone remodeling activities is high. Therefore, an HD implant with a machined implant surface in the crestal area has a reduced risk for peri-implantitis.

This assumption is supported by recent clinical studies. The most important one is the study by Derks et al. (2015, 2016) comparing one HD implant system with two non-HD implant systems in Swedish patients. HD implants showed significantly lower failure rates (odds ratio of 5 and 6), and the lowest prevalence of peri-implantitis (odds ratio of 3.5 and 3.7) after nine years of function.

A recent 10-year study on 407 patients with 1,482 non-HD implants by Windael et al. (2021) reported that early bone loss of >0.5mm during the first year of function was a predictor for peri-implantitis. This resulted in a much higher prevalence of peri-implantitis. At 10 years, the failure rate was 5.2%, and the prevalence of peri-implantitis 11.8%. This study can be well compared with a 10-year study on 304 patients with 511 HD implants at the University of Bern (Buser et al. 2012). This study showed a failure rate of 1.2%, and a prevalence of peri-implantitis of 1.8% after 10 years of function. The examined implants were tissue level implants of Straumann, the first HD implants used in the market since 1986.

It's time to realize that we have a pandemic of peri-implantitis around the globe. The problem is triggered by colleagues with a poor surgical education, a lack of surgical talent, and not enough surgical experience. When an implant surgery is conducted with a low quality, the implant often has an exposed micro-rough surface to the peri-implant sulcus at completion of healing, and the development of peri-implantitis within a few years is most likely.

The easiest way to reduce this risk is the utilization of HD implants as proposed by Dr. Tarnow 28 years ago. Most of the major implant companies do have HD implants in their product line, but the clear majority of sold implants are non-HD implants. It's time to convince these companies to change that. We need a second paradigm shift in the market towards HD implants to reduce the prevalence of peri-implantitis. This would not only be a benefit for our patients, but also in the interest of all dentists involved in implant dentistry, and all implant companies.

References in this article are available via scanning the QR code.

Back to the future of osseointegration – The origin and rationale of the hybrid implant design 28 years ago

By Dennis P. Tarnow, DDS, Academy News *Guest Contributor*

As we all know, there are two main reasons that cause implants to fail. One is that the bone and the amount of integration is insufficient to withstand the forces applied to an implant via functional occlusion and/or parafunctional habits. And either of these forms will then lead to an outcome of occlusal overload. The other main reason for failure is bacteria related and this is termed peri-implantitis.

During the 1980s when we started doing implants, most of us were using fully machined implants like the original Brånemark implant. This implant and its corresponding smooth surface made of titanium provided a unique surface leading to a novel biologic reaction to what we all know today as osseointegration. And this response led many of us to an understanding and belief implants could change dentistry and become a mainstay in our armamentarium for our patients. This was particularly true for the fully edentulous patients that we were treating during that decade.

Dr. Dennis P. Tarnow

In the late 1980s and early 1990s, other treatment protocols were established and we started to use implants for single teeth and partially edentulous situations. Many of these implants were being placed in the posterior mandible and maxilla where the bone is softer. In addition, we also started to do sinus lifts which required us to place implants into grafted bone, which was not always as dense as the patient's own bone. As these changes occurred, the desire to accelerate and increase bone to surface area contact evolved. This led to exploring different surface textures like SLA, TPS, or HA coatings, which were believed to have a higher initial success rate in these softer bone areas.

With this new awareness, companies all rushed to texture the surface of their implants. In fact, this worked very well to get a higher initial survival rate after loading. This was clearly true in grafted sinuses where the implants could be loaded earlier than the fully machined implants and still have a higher survival rate.

As companies started to develop new surface characteristics, a new problem started to emerge from coating the entire implant to the top of the implant. This was a knee jerk response that opened the implants to the problem of possible exposure of these textured rougher surfaces to the oral cavity and plaque and associated biofilms. This led to a new problem that we rarely saw on the fully machined implants - that was peri-implantitis.

What was forgotten by the companies was that biologic response to abutment connections, which causes the biologic width on the implant to move down to the top of the implant on bone level implants after multiple disconnections. This then allows for these rough surfaces with time to frequently get exposed. This problem was not seen in the first year like the problem of occlusal overload of the bone which would show early on.

This peri-implantitis problem sometimes took a few years to show up with increased loss of bone from the crest down. Therefore, the implants were still integrated and surviving but they were losing bone over the years and were not always successful.

So, from not seeing significant bone loss in our patients during the eighties, we started to realize that patients were coming in with increased problems with bone loss and not just mucositis as we tended to see on the top of machined surface implants.

Therefore, it occurred to me that we might combine the best of both surfaces into one implant. Why not keep the top two or three millimeters of the implant machined to resist peri-implantitis which can still integrate, and put the textured roughened surface in the middle and apical part of the implant to help obtain faster and higher percentage of bone integration? In 1993, the concept was first published showing the prototype of a newly defined category of the hybrid implant. That was 28 years ago[1] (Fig. 1).

Fig. 1: Prototype of the Hybrid Implant concept from 1993. Published in Ref. 1.

It is amazing to me that it took so long of for many companies to realize this concept makes sense for the short- and long-term success and survival of the implants that we put into our patients' mouths. Many companies who rejected the hybrid implant concept early on may have unintentionally contributed irreversible bone loss and implant failure.

In my opinion, this may have also impacted some of the leading implant companies over the years going from being the most used implants to falling behind other companies who had the foresight to see this problem and make a change.



Fig. 2: Some of the hybrid design implants that are available today.

It is extremely encouraging to see today so many of the major implant companies have followed a hybrid implant design and have a less rough surface at the coronal third of the implant, even if the top is not machined and that they put their highly textured surfaces in the middle and apical thirds of their implant (Fig. 2). Bravo!

This will hopefully bring us to a point where we minimize the bone loss around our implants over time and have a higher survival and success rate long term for our implants.

Thank you for asking me to share my perspective on the evolution and origin of the hybrid implant. It is honor for me to present this information to my esteemed colleagues of the Academy of Osseointegration.

References

1. Dental Implant in Periodontal Care by Dennis P. Tarnow in Current Opinion in Periodontology 1993, Current Science ISBN 1-870485-58-0 ISSN 1065-626X

Osseointegration Foundation receives approval for 2022–2023 board

The Osseointegration Foundation recently received approval for its leadership slate by the Academy's board at its October 9, 2021 meeting. The 2022 – 2023 OF board of directors, which includes the appointment of its secretary/treasurer and two new directors will be as follows:

Officers

President: **Andrea L. Henderson**, DDS

Vice President: AO Life Fellow **Russell D. Nishimura**, DDS

Secretary/Treasurer: **Hans-Peter Weber**, DMD

Past President: **Wendy M. Croll Halpern**, DMD

Directors

AO Fellow **Tara L. Aghaloo**, DDS, MS, PhD; AO Past President, (1 year only)

Mehrdad Favagehi, DDS, MS

Nipul Tanna, DMD, MS

New: **Harriet K. McGraw**, DDS

New: **James S. Gurley**, DDS

Dr. McGraw is a general dentist who has practiced in Harbor Springs, MI, for 30 years. The emphasis of her practice is on dental implants and complex restorative cases. She treats difficult cases with a team approach, working closely with various dental specialists and laboratory technicians. Dr. McGraw has been active with the Academy, serving as the most previous editor of *Academy News*. "AO and OF lead the profession in maintaining the highest standards for educating clinicians and supporting research in the field of dental implants," she said.

Dr. Harriet McGraw

Dr. Gurley has spent 40 years as a clinician, including more than 35 as a volunteer faculty member at Case Western Reserve University School of Dentistry. He has been active with the Academy's Research Submission Committee for many years, currently serving as chair, and previously was a member of the GP Recruitment Task Force.

Dr. James Gurley

"I am looking forward to bestowing more research grants and helping decide who should receive those funds from the Foundation," said Dr. Gurley.

IMPLADENT LTD
REGENERATIVE SOLUTIONS

Contact 800-526-9343
or Shop Online at
www.impladentltd.com

Join us at the 2022 AO Annual Meeting in San Diego, CA and Attend the Impladent Ltd Seminar on Thursday February 24, 2022 at 8:00am to Receive Bonus Show Specials

Buy 4 Boxes Get 1 Free

Must Attend 2022 AO Annual Meeting and Visit Booth 1100

OsteoGen® Plug

OsteoGen® Non-Ceramic Bioactive Crystal Bone Graft*

Type I Bovine Achilles Tendon Collagen

No Membrane Required For Tooth Extraction

OsteoGen® Strips



OsteoGen® Bioactive Resorbable Calcium Apatite Crystals & Type I Bovine Achilles Tendon Collagen

OsteoGen Malleable Bone Block™

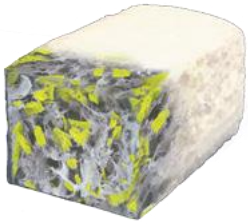

Used for Ridge Modeling or Sinus Elevation can be cut with scissors

Impladent Ltd. Corporate Forum

Thurs Feb 24, 2022, 8:00 - 9:45am

Achieving Synergy in Surgery: From One-Step Ridge Preservation to Onlay Grafting and Enhancing the Implant Site • Robert J. Miller, DDS

This seminar discusses one step ridge preservation as well as onlay grafting and how to enhance the implant site by combining novel biomaterials with autologous growth factors. From simple and cost-effective socket grafting without the need for a membrane, to more advanced clinical concepts in bone regeneration. This course covers a spectrum of pliable preformed shapes used for bone grafting procedures for implant placement. Surgical techniques and novel biomaterials will be discussed including Synthetic Bioactive Resorbable Calcium Apatite crystals, OsteoGen® Plugs and Strips as well as the resorbable Malleable OsteoGen® Bone Block which can be used with Tri-Star® Screws.

*That controls migration of connective tissue (Spivak 1990; Ricci 1992; Valen 2002)

Scan for references

Contact 800-526-9343 or Shop Online at www.impladentltd.com

Dr. Torsten Jemt selected as 14th Nobel Biocare Brånemark Osseointegration Award winner

Torsten Jemt, DDS, PhD, is the 14th recipient of the Nobel Biocare Brånemark Osseointegration Award. Today, he holds a combined scientific position at the Faculty of Odontology as an associate professor, and as a clinical scientific coordinator at the Dental Health Service of the region of Västra Götaland, Sweden.

This annual award, made possible by a grant from Nobel Biocare, is bestowed by the Osseointegration Foundation (OF), AO's philanthropic arm. It honors an individual whose impact on implant dentistry is exemplary in any or all of the Foundation's mission categories: research, education, and charitable causes.

"I was surprised and felt very honored," described Dr. Jemt about his reaction upon learning he was the 2022 recipient.

Dr. Jemt started collaboration with Prof. **Per-Ingvar Brånemark** in 1978 and was involved in the development of the first single implant abutments which he designed in 1983, and the first CAD/CAM titanium frameworks in 1996. He co-founded the Brånemark Clinic in Gothenburg in 1986 together with **Ulf Lekhom**, DDS, PhD.

According to Dr. Jemt, Prof. Brånemark was very focused on the patient and how to take care them. He was also focused on biology and saw the response from the host tissue to be crucial for the treatment result. "In the early days; we should treat the implants with care; only titanium in contact with hard and soft tissue (prosthesis components above the tissue), good access for cleaning and avoid probing into the tissue adjacent to the implant," said Dr. Jemt.

He continued, "During the early 1980s, a major focus of the team was the testing of new clinical applications and the development of new implant components. In 1982, I was asked to create prosthetic components for the single-implant application, and during 1982 – 1984, Dr. **Tomas Janson** and I treated the very first single-implant patients in the world using osseointegration. I had frequent contact with the Brånemark team and became a part of the team in the early 1980s, and treated my first patient with an implant-supported prosthesis in the late 1970s."

Dr. Jemt was co-chairman of the Brånemark Clinic between 1986 and 2000, and chairman between 2000 and 2009. Dr. Jemt became a board-certified prosthodontist in 1982 and received his PhD degree in Prosthodontics in 1984. He has published over 170 scientific publications and lectured worldwide since 1983.

His current scope of work with Dental Health Service is still implants – and the interaction between the foreign body implant and the patient/host tissue. Try to see the entire patient and how the individual patient's immune system may interact with the implants and may also be reflected in the general health of the patient.

"My professional background prior to 1986 and the period immediately afterward, were an important basis for my clinical experience with osseointegration. My long-term experience with osseointegration is that we have indeed come a long way. We need to learn more about ourselves as clinicians, why and how we choose different treatment techniques, and how short- and long-term clinical results and complications interact with our choices and the individual patients we treat," concluded Dr. Jemt.

Previous Nobel Biocare Brånemark Osseointegration Award honorees are (in chronological order) **Per-Ingvar Brånemark**, MD, PhD; **William R. Laney**, DMD, MS; **George A. Zarb**, BChD, DDS, MS; **Daniel VanSteenberge**, MD, PhD; **Ulf Lekholm**, DDS; **Daniel Buser**, DDS, DMD; Professor **Tomas Albrektsson**; **Stephen M. Parel**, DDS; **Ole Jensen**, DMD; **Steven E. Eckert**, DDS; **Kenji W. Higuchi**, DDS, MS; **Jan T. Lindhe**, PhD; and **Patrick J Henry**, BDSc, MSD, DDS. The selection process involves members of the OF's Titanium Society proposing distinguished candidates.

All Titanium Society members and a guest of their choice are invited to attend the annual Titanium Society breakfast meeting, Saturday, February 26, at 7:00 am, where Dr. Jemt will give an exclusive presentation for Titanium Society members and their guests. He is also scheduled to present as part of the 2022 Opening Symposium.

Positions are still available in the Titanium Society, which is limited to supporters who have pledged $10,000 total in past and future contributions over a four-year period. The Titanium Society's membership is limited to 100. Anyone interested in becoming a Titanium Society member may find a downloadable membership application on the OF section of the Academy's website (www.osseo.org) or by contacting the Academy's Executive Office at 847-439-1919, or by email at academy@osseo.org.

Dr. Torsten Jemt

Updated 10 keys checklist for immediate implant placement at maxillary central incisor sites

By Academy News *Guest Contributors AO Fellow Robert A. Levine, DDS; Debora Reis Dias, DDS; AO Fellow Jeffrey Ganeles, DMD; Ping Wang, DMD; Maurício Araújo, DDS, MSc, PhD*

Immediate Implant Placement (IIP) following tooth extraction is an attractive treatment modality, given its shortened treatment time and reduced surgical trauma. IIP in the esthetic zone has been widely considered a complex procedure that demands not only clinician experience, but also knowledge of the site anatomy, along with surgical training and use of an evidence-based checklist.

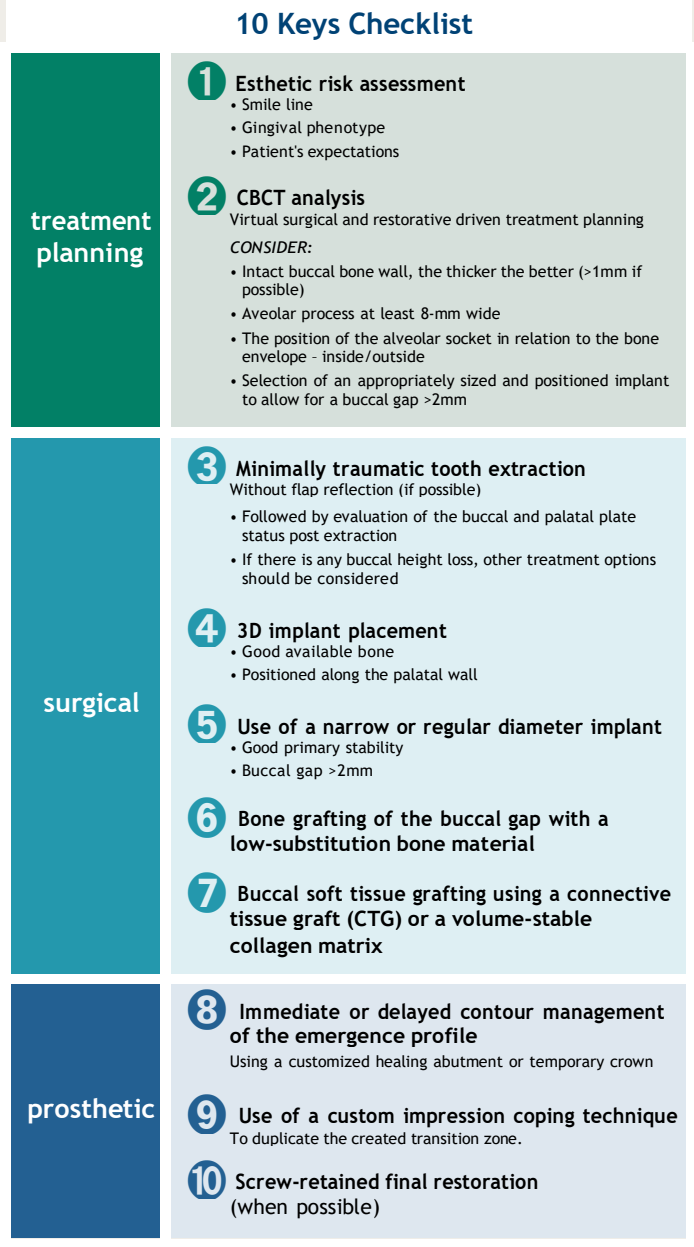

Fig 1. 10 keys for successful IIP at maxillary central incisors.

Renouard et al. (2017) addressed the role of human factors as the root causes of many complications/failures in dental implant practice. As in the aviation field, checklists should be seen as one of the safety nets for preventing undesirable consequences.

Taking into consideration the challenges of IIP at esthetic sites, Levine et al. (2017) proposed a checklist that included 10 keys to help clinicians achieve predictable outcomes (Fig. 1). The list has two treatment planning, five surgical and three prosthetic keys. To achieve optimal esthetic outcomes, all 10 keys must be followed in sequential order. If one of the planning or surgical keys cannot be completed, immediate implant placement should be aborted.

Site selection

The first step is to thoroughly get to know the patient in order to put them at ease and establish a rapport. The site to be treated should be evaluated both clinically and radiographically (CBCT). Patient smile line and expectations should be assessed as part of an Esthetic Risk Assessment (ERA).

The anatomy of the surgical site obtained from the CBCT reconstruction is of pivotal importance, as it determines whether the alveolar process/basal bone dimension is adequate to house an implant and to provide primary stability. If the CBCT evaluation reveals that the site anatomy is inadequate, IIP is contraindicated. To avoid esthetic complications, the recommendation then would be for either early implant placement with GBR or ridge augmentation six-to-eight weeks later.

A recent study by our team described anatomical predictors for successful IIP along with ridge preservation. Twenty-five implants were placed at maxillary central incisor sites and compared to the undisturbed contralateral sites. All implant sites underwent the same intervention: tooth extraction, IIP and socket grafting with Anorganic Bovine Bone (ABB).

The findings of the study demonstrated that after approximately five years in function, the alveolar ridge dimension was preserved 30-100% when compared to the corresponding untreated sites. Some sites were better preserved than others. Statistical models were used in an effort to explain the variability.

It was observed that the thicker the buccal bone 3mm from the crest, and the wider the alveolar process at the same level, the better the ridge preservation. Furthermore, socket

Fig 2. CBCT reconstructions illustrating two different case scenarios for IIP: a. Alveolar process <8mm in width, with a thin buccal wall and the alveolar socket outside the bone envelope. b. Alveolar process ≥8mm wide, with a thicker buccal wall and the alveolar socket inside the bone envelope.

sites outside the bone envelope presented a greater risk for poorer outcomes (Fig. 2). And finally, the wider the gap between the implant and the buccal bone, the lower the amount of ridge resorption.

To summarize, during virtual tomographic planning, the clinician should observe if: (a) there is an intact buccal wall, the thicker the better; (b) the width of the alveolar process is ≥ 8mm; (c) the alveolar socket is inside the bone envelope; and (d) the implant is at the ideal restorative position in addition to the buccal gap measuring > 2mm. Narrow or regular diameter implants are preferable. Planning for a computer-assisted implant surgery is recommended.

Implant placement and grafting

The surgery should follow minimally invasive protocols, with flapless tooth extraction, IIP in the planned position. Guided surgery is often recommended for achieving accurate positioning.

Filling the gap between the implant and the buccal bone with a low-substitution bone material is essential. Studies from our group have shown that gaps > 2mm grafted with ABB can preserve >90% of the pristine alveolar process dimension and promote a stable newly formed buccal bone wall after a mean interval of five years.

The first gap study included 28 implants immediately placed at maxillary central incisors with socket grafting (ABB) and 28 contralateral control sites. The sample was divided according to the gap dimension measured during surgery, resulting in two groups: the wide gap group, > 2mm, and the narrow gap group, ≤ 2 mm. After one-to-five years in function, a CBCT scan was obtained. The total cross-sectional area of the ridge in the wide gap group showed minor reduction, 8.8%, while the narrow gap group presented a significant ridge modeling of 41%. Thus, the wide gap was able to preserve more than 90% of the ridge dimension.

On the second gap study, the effect of the gap on the buccal bone wall was evaluated. Forty-two patients treated with 53 immediately placed implants were included, following the same surgical procedure. The patients were divided into two groups according to the dimension of the gap. After one-to-five years, it was observed on CBCT reconstructions that the thickness and height of the buccal bone was significantly greater in the wide group. Thus, a >2mm-wide buccal gap should be planned virtually and grafted, to allow for a stable buccal bone wall along the implant surface.

These studies showed that the gap dimension, as well as grafting the gap is important. However, it is well documented that grafting reduces the remodeling process but does not eliminate it. To compensate for this minimal remodeling, additional procedures are often required, such as soft tissue grafts.

Our group also studied the effect of Connective Tissue Grafting (CTG) following IIP and ridge preservation at maxillary central incisor sites. Sites treated with a CTG exhibited significantly better esthetic outcomes when evaluated using the Pink Esthetic Score/ White Esthetic Score index (PES/WES). Other studies have shown the importance of CTG to avoid mid-buccal recession and for phenotype conversion. Use of CTG or a soft tissue substitute is highly recommended.

Fig 3. Clinical case illustrating the use of the 10 keys.

Prosthesis

The surgery is completed with soft tissue contour management, accomplished by using either a customized healing abutment or a provisional restoration.

Following integration and healing, the marginal tissues are captured during impression taking or scanning, and, when possible, a screw-retained prosthesis is fabricated and delivered.

In conclusion, well-documented evidence has shown that more predictable outcomes are achieved when using the 10 keys checklist described above. It helps clinicians achieve optimal outcomes when placing IIP with ridge preservation.

References available upon request.

Research submissions reflect high quality, core values of Academy

Every Academy Annual Meeting, student and professional researchers are invited to submit their original research and clinical cases in the field of implant dentistry for presentation and recognition.

As a result, nearly 200 abstracts and ePosters for Clinical Innovations, Oral Research (Scientific and Clinical), and ePosters (Scientific, Clinical and Case Studies) are received.

It is then the job of the Academy's Research Submissions and ePoster committees to collaborate and review all submitted abstracts to determine which researchers will be honored. Awards for the best oral presentations and ePosters take place during the Academy's Annual Business Meeting, which this year will be held on February 26 at the San Diego Convention Center.

"The excellence that comes through the Academy of Osseointegration just can't be topped. I look forward to it every year," said **James S. Gurley**, DDS, chair of the Research Submission Committee. "I believe that is because it is all fresh information, as the Annual Meeting is held toward the beginning of the year."

According to Dr. Gurley, each abstract receives a grade based on originality, significance, relevance, and quality. While all categories are important, significance and relevance need to stand out the most. With today's technology, quality is a given. The trend in research submission is bone and tissue engineering, seemingly among periodontists. PhD's are very good about their submissions, he shared.

"Everyone on the committee brings a different perspective and is good hearted. We are balanced among the specialties, reflecting the core essence of the Academy."

For the 2021 Virtual Annual Meeting, the Academy spearheaded the submission of video presentations for all the abstracts, which helped to provide connection between presenters and registrants participating from their homes or offices.

"The audio and video presentations enabled the participants to remotely present and keep the meeting going during the difficult times. I can certainly tell you that the digital approach for posters improved the gradeability of ePosters, as the reviewers are able to see the entire presentation with the images remotely, and can better understand the candidate posters," said **Burak Yilmaz**, DDS, PhD, chair of the ePosters Committee.

"Videos are the holy grail — I really like them! It gives you the opportunity to stop the presentation contemplate the detail," said Dr. Gurley.

The Academy was also a front runner among dental organizations in implementing ePosters. "The future thinking and commitment to its scientific core values with the addition of ePosters allowed the Academy to be the first dental organization to fully implement them with an average volume of 200 submitted each year," said **Mehrdad Favagehi**, DDS, MS, credited with implementing ePosters during his term as chair of the Research Submissions Committee in 2014. "Members can access ePosters from current and past Annual Meetings via the Academy's website, which also allowed dissemination of implant scientific and clinical innovations during the shutdown of the COVID-19 pandemic."

"I really like what the ePosters and abstracts bring, from grad students on up. Everyone is so passionate about implant dentistry at the Academy's Annual Meetings. Anything they know they are glad to share," added Dr. Gurley.

"We are excited to have over 130 ePosters at the meeting this year and the video adds another dimension for those unable to attend the meeting in person," concluded Dr. Yilmaz.

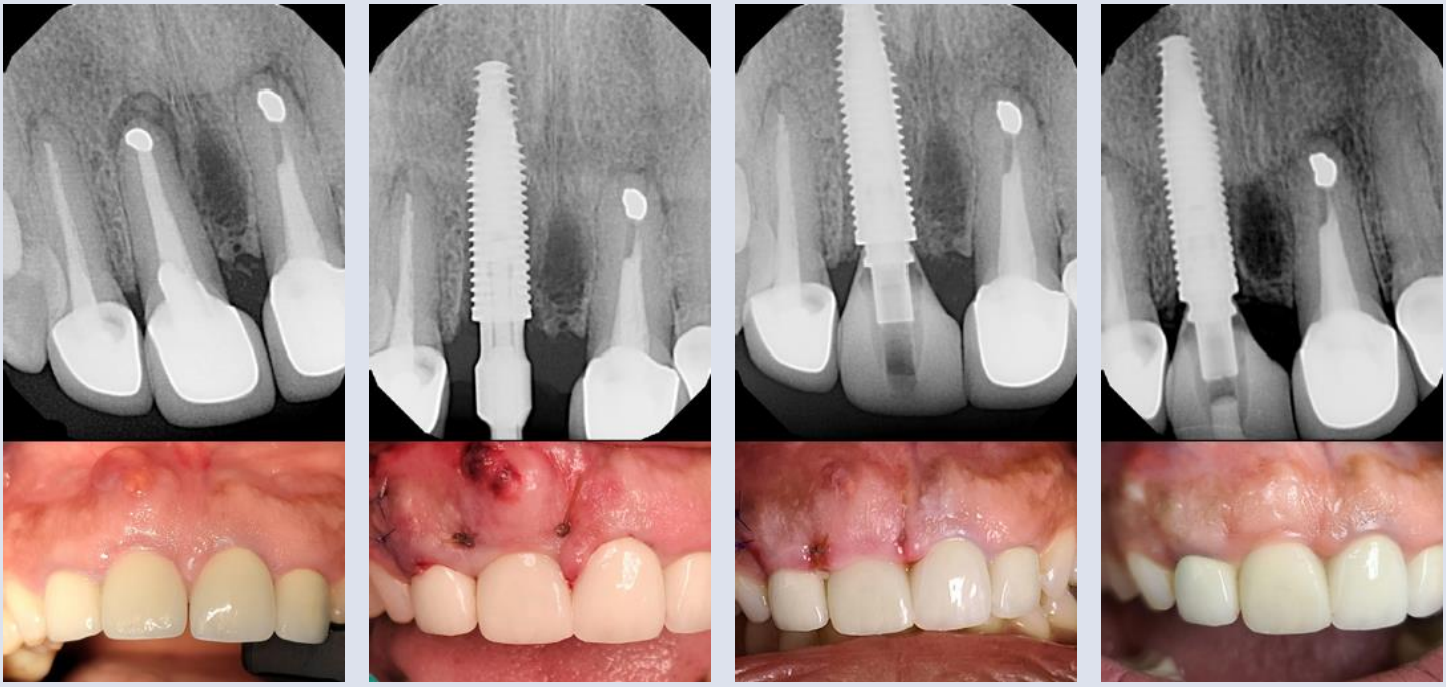

Pre-Op *Day of Surgery* *One Week After Surgery* *One Month After Surgery*

Immediate implant placement and provisionalization

By Riad Almasri, DDS, Academy News *Editorial Consultant*

I believe that no patient should leave your office without teeth.

Social media has dramatically increased patients' awareness of what is possible, and their expectations are at an all-time high. Today, immediately placed implants into a fresh extraction socket have very high survival and success rates. They provide clear advantages: they shorten the treatment time by reducing additional surgical appointments, allowing earlier contouring of the soft tissue for more predictable esthetic results.

When Prof. **Per-Ingvar Brånemark** introduced the osseointegration concept in 1977, no one could have predicted how rapidly the protocols would evolve over the following years to shorten the prosthetic load time and culminating to today's immediate implant loading concept. This has offered patients the option to satisfy various esthetic demands prior to the completion of osseointegration. The following includes a brief description about our technique.

After extraction, existing periapical lesion and granulation tissue must be curetted completely, and chlorhexidine gluconate 0.12% oral rinse is used to clean the socket. The implant is placed following the osteotomy, and a torque value of at least 35 Ncm must be achieved. The impression coping is placed and tissue is sutured prior to making the impression. Heavy body PVS is used for the tray and medium body PVS is used around the impression coping.

While the lab technician is fabricating the provisional, a healing abutment is placed, and any bone grafting is used at this time before suturing again. The fabrication of the acrylic provisional crown is completed in the lab and inserted in the patient's mouth. Proximal contacts are adjusted as needed. Occlusion is verified in MICP, and protrusive and laterotrusive movements are adjusted to have no contact with the opposing teeth. The screw access holes are sealed with teflon tape and temporary filling material.

The patient must be seen at one-week and three-week postoperative appointments to evaluate the healing of the surgical sites and evaluate the occlusion. The most important post op instruction is avoiding any force from occlusion on the provisional.

The risk to failure of an immediately loaded implant increases when micromovements are present, with a tolerated range of 50 to 150 µm. Thus, achieving good primary stability is key to the long-term success of an immediately loaded implant.

"A generation which ignores history has no past — and no future." *Robert Heinlein*

By Paul A. Fugazzotto, DDS, Academy News *Editorial Consultant*

Salvation arrived in the late 1970's when Prof. **Per-Ingvar Brånemark** unveiled his "magical" osseointegrating titanium implants.

Gone were the days of offering patients a choice of either full dentures with their inherent limitations, or iterations of oral implants plagued by short-and-long term unpredictability. We now had the means by which to dramatically improve our patients' treatment outcomes and quality of life.

Best of all, the lack of a "peri implant ligament" eliminated a well-established pathway for bacterial byproduct penetration and establishment of inflammatory diseases akin to periodontitis. Reconstructive therapeutic predictability had arrived.

The next land to conquer was that of partial edentulism. Bilateral distal extension removable prostheses, viewed by many as pre-full denture appliances, would become a thing of the past. Implants could be utilized as pier abutments, adding support to existing teeth when fabricating long span prostheses. Many experienced and talented clinicians viewed osseointegrating implants as "non-decaying teeth" which would help stabilize a patient's remaining teeth beneath a fixed prosthesis.

Happy days were here again!

Not so fast. To quote doc from "Back to the Future:" "Egad!".

Rigidly attaching implants to natural teeth posed their own unique set of concerns. If the prosthesis' framework did not fracture under function due to the displacement differential between an osseointegrated implant and a tooth surrounded by a periodontal ligament, the implant essentially supported the prosthesis. The magnitude of the forces placed on the implant in such a scenario often led to peri implant bone loss and/or disintegration.

What solutions could dentistry offer? It was time to travel back to the future.

At first, these forays into the past were too limited in scope, searching for technical solutions rather than overarching understanding.

Copings were placed on the natural tooth abutments, *a la* **Morton Amsterdam** and **D. Walter Cohen**, and one-piece fixed prosthesis were secured by the natural teeth and implants. This approach proved problematic, as the natural teeth often "walked out" from beneath the prosthesis.

The concept of an intra-mobile element to mimic the displacement of a natural tooth within its ligamental housing, and t-block attachments to the implants, were introduced by Kirsch, Ackermann and Neuendorff. Unfortunately, the required technical acumen and cost of this approach was prohibitive for all but a few.

In addition, the invulnerability of osseointegrated implants proved to be a fallacy. Rather than protecting implants through the elimination of a ligament, and thus a primary means of inflammatory cell progression, the osseointegrative bond rendered the impact more susceptible to functional and parafunctional forces. These forces proved disastrous to the peri implant supporting bone, and bone resorption under function was identified a serious detriment to implant survival over time.

Clearly, the answer lay not in the adoption of clinical "tricks of the trade" from the past. More was required.

> ***"The great wars of the present age are the effects of the study of history."***
>
> — Friedrich Nietzsche

While not advocating a return to the days of the barber-surgeon-dentist, there is much to be taken from that era. The inextricable entwinement of dentistry and other branches of medicine is today a well-accepted postulate. Unfortunately, the conceptual and clinical advances of the last 100 years have all too often focused upon techniques at the expense of dentistry's rightful place as a branch of medicine. This is both unnecessary and dangerous. Exquisite technical execution within the context of sound medical practice yields unmatched treatment outcomes and improved patient quality of life.

Traveling back to the future consists of striving to understand the past in all of its applicable ramifications and applying such lessons when developing guidelines for therapy today and in the future.

Patient intake, examination and diagnosis are carried out with the understanding that the potentials of care

are governed by the envelope of overall patient health. Systemic influences upon short-and-long-term therapeutic successes must be assessed and accounted for in treatment planning and delivery of care.

All therapies must be supported by the Everest of biologic understanding developed in the past centuries up to the present. While there is of course always more to learn, in many instances we, to quote a former New England Patriots quarterback, "have the answers to the test." It is no longer acceptable for a clinician to justify his or her therapeutic approach with the phrase "it works in my hands."

Parafunctional forces have to be understood, recognized and ameliorated through the use of neurotoxins, and/or equilibration and appropriate appliances. Sleep disorders must be identified and treated, whether it is by the dentist or a qualified sleep physician.

The impact of occlusion on the success and failure of care must be understood and incorporated into all treatment plans and therapies.

Such interdisciplinary, comprehensive treatment planning, the sine qua non of successful therapies, is a modern iteration of the well-established tenets of periodontal prosthesis, as espoused by the BU-UPENN-UWASH triumvirate and others decades ago.

Translation of this understanding to today's clinical environment, and its extension forward, is truly a journey "back to the future."

"Evolution is not replacement of what has gone before. Evolution is at its core advancement upon the shoulders of the past."

— C. Callisto Caputo

Publications have confirmed that implant therapies characterized by thorough examination, insightful diagnosis, comprehensive treatment planning, meticulous technical execution, utilization of the finest available materials, and consistent long-term follow up within the context of efforts to maximize systemic health result in an implant success rate of over 99% at 10 years in function. This is not good enough.

Maximization of overall treatment outcomes and patient quality of life must always be the ultimate goals of care.

What are our present day goals and aspirations with regard to patient care and therapeutic excellence?

To quote David Byrne:

"Same as it ever was."

View the Top 10 ePosters

Be on the lookout for the posting of 2021's top 10 ePosters as one of the latest initiatives on the AO DocMatter Community.

Selected by the Academy's Research Submissions and ePoster committees, these ePosters will be published weekly on DocMatter, with a video introduction by the presenter about their topic. Each post will include the ePoster and DocMatter's easy to use platform for discussion among your peers and each of the authors.

This initiative will be introduced by a short video from Academy Board Director **Robert R. Lemke**, DDS, MD.

"Normally, the posters are shown only once a year at the Annual Meeting, as well as available via the Academy's website. Now with their integration into DocMatter, you can watch and interact with your fellow members and colleagues," said Dr. Lemke. "We look forward to seeing you on DocMatter."

Editor's Note: The AO DocMatter Corner is a regular section of Academy News *to highlight updates about the Academy's newest member benefit. Members are encouraged to regularly log in to this secure and confidential online forum for exchange of clinical and scientific information, facilitate high quality clinical and practice management discussions and collaboration over a variety of topics at: https://www.docmatter.com/.*

H & H Company

FINEST QUALITY INSTRUMENTS

ORAL SURGERY • PERIO • IMPLANT
11888 N Tracey Rd. • Hayden, ID 83835
800-491-9989 • www.hhcompany.store

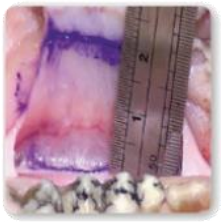

WEN Tension Release Comb acc. to Dr. Wen, DBGM

WEN Tension Release Comb can be used to extend the split flap by combing, to easily achieve complete coverage. Depending on the condition of the soft tissue, flap extensions of 15 to 20 mm are possible.
SKU 41.865.01

Tunneling Instruments

Tunneling instruments find their application in the preparation of flaps or subsequent reconstructions of the alveolar ridge or for root coverings with a connective tissue grafting. These instruments allow minimally invasive tunneling preparation to avoid large openings.
SKU 46.040.30

NIZAM Ring Punch

Keratinized tissue grafts (KTGs) are widely used in modern implantology for peri-implant soft tissue management and in various periodontal plastic surgical interventions such as root coverage, papilla reconstructions and alveolar ridge preservation. KTGs are accepted as the gold standard for root coverage procedures and peri-implant soft tissue augmentation techniques, since they have higher success rates and greater esthetic outcomes. The Nizam Ring Punch, offered in a latch type connection, makes harvesting KTGs quick and easy.
SKU 08.921.00

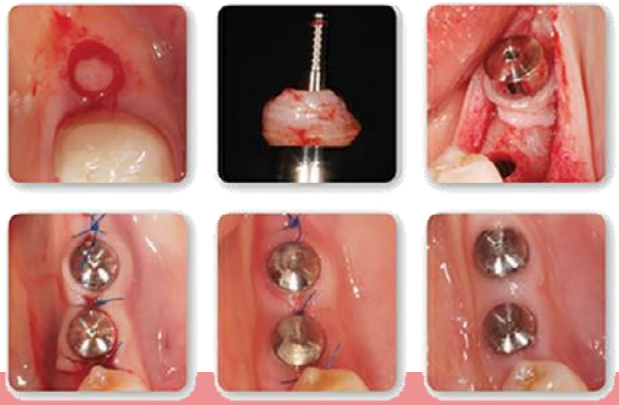

800-491-9989 • www.hhcompany.store

ZEPF dental

Digital workflow in surgery

By Edgard El Chaar, DDS, MS, Academy News *Guest Contributor*

When I was training in the early 1990s, I saw the evolution of implant dentistry from one implant size, one grafting material, and one membrane to a vast array of options that can be overwhelming at times to the clinician. I also witnessed the metrics that were postulated leading to a 3D implant placement, as well as the prosthetically driven dental implant placement concept.

These have led to fundamentals in implant dentistry aiding clinician in the surgical placement of dental implants. Technology has always been available to assist clinicians in implementing those fundamentals.

Fig. 1

Digital dentistry encompasses all the images that we take and are instantly processed and displayed to us on a computer screen (i.e., photographs, radiographs, cone beam tomography, and intraoral scans). There are universal languages for distributing and utilizing these images such as JPEG, STL and DICOM, as well as software specific languages. Today, the entire digital workflow is an open platform where data is exchanged using these universal languages, providing the clinician with a wealth of information.

The question is whether it is being used to its full potential by most clinicians. The answer is no. In our dental community, there is an apprehension based on: Is it worth the investment? Do I really need it? Without a doubt, the answer to these two questions is a capital YES.

Why is that? In our daily surgical dental practice, we perform a variety of implant procedures. These include tooth extraction with either site preservation or immediate implant placement, a long-standing bridge that needs replacement and the pontic area that requires a dental implant, and even a large bony defect that necessitates a major ridge augmentation (Fig. 1). We are used to assessing the situation by looking at a CBCT image and attempting to plan the 3D implant placement without the 3D component.

Compiling the digital scan over the CBCT allows us to gain a much deeper understanding of the tissue, whether it is thin or thick in the case of extraction socket, the presence or absence of buccal plate in relation to the gingival margin, and the apical topography, which is also in the case of extraction socket. The ability to digitally synergize the prosthetic crown for immediate implant placement, which aids in visualizing the emergence profile in relation to the depth of the implant and its lingualized placement, is a significant benefit that digital workflow can provide.

In the case of an edentulous site, the ability to superimpose digital wax-up and assess the feasibility of the placement in a prosthetically driven manner, as well as determine if bone augmentation is required, and if so, the ability to print the rendering of that area in a model and prepare ourselves for surgery, is an incredible immeasurable added value.

To summarize, we are living in an amazing time of integrated technology, and we have only scratched the surface of what we can achieve with this technology; let us open our minds and embrace it.

References in this article are available via scanning the QR code.

Dr. Edgard El Chaar

The ZAGA concept for decision-making in zygomatic osteotomy

By Academy News *Guest Contributor Carlos Aparicio, MD, DDS, MSc, MSc, PhD; and* Academy News *Editorial Consultant Yong-Han Koo, DDS*

Zygomatic implant therapy has allowed clinicians to provide an effective means of prosthetic rehabilitation for patients with severe maxillary atrophy.

The previously described systems of placing zygomatic implants, such as Prof. **Per-Ingvar Brånemark**'s original surgical procedure, the sinus slot technique, or the extra-sinus technique, promote specific surgical approaches that are universally applied to *all* patients.

However, varying morphologies of the edentulous maxilla have been identified between different individuals and even within the same person[1]. Therefore, adopting the same osteotomy type in all situations can frequently result in bulky prosthetic constructions, impaired hygiene, sinus complications, or soft tissue dehiscence.

The Zygomatic Anatomy-Guided Approach (ZAGA)[1-3] is described as a refinement of the extra-sinus technique[4].

Conversely, this concept of placing zygomatic implants involves a 'patient-specific' therapy that applies to all atrophic maxillary anatomies.

Indeed, the essence of the ZAGA concept is in understanding the possible anatomical variations between individuals; even in different sites for the same patient. Success therefore, is better achieved by providing a zygomatically anchored rehabilitation based on distinct anatomy (Fig. 1, 2).

Surgical management of the implant site is guided by specific prosthetic, bio-mechanic and anatomic criteria. Moreover, the primary goals of any ZAGA osteotomy are to achieve maximum stability of a prosthetically-planned, ideally-positioned zygomatic implant, optimal AP distribution, and implant trajectory. When these goals align, we may prevent potential long-term complications, including oral-antral fistulas or soft tissue dehiscence[5].

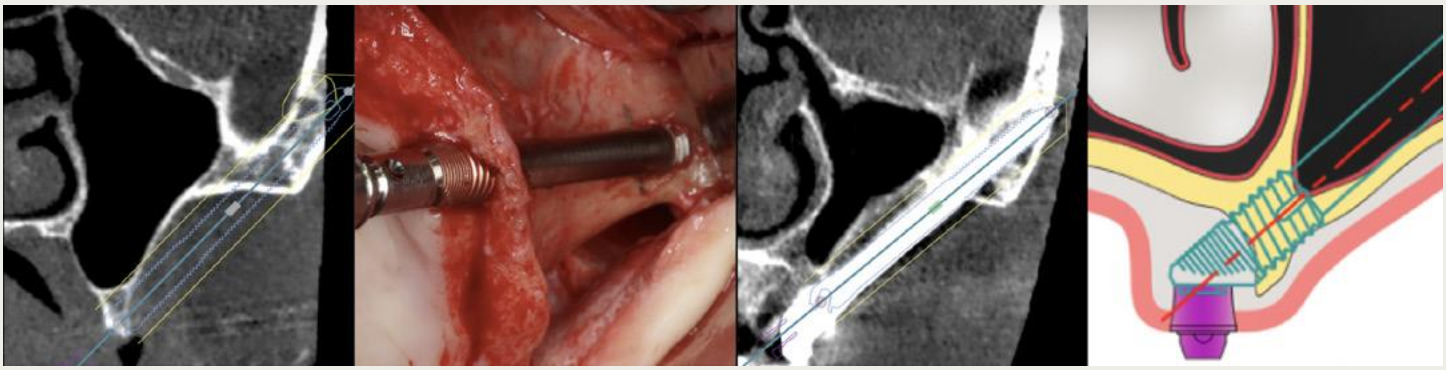

Fig. 1: Tunnel-type osteotomy. When the bone architecture at the nasal/sinus floor level is considered sufficient to house the implant neck (that is ≥ 4 mm high x 6-7 mm wide), attempts are made to place the implant through it using a tunnel-shaped osteotomy.

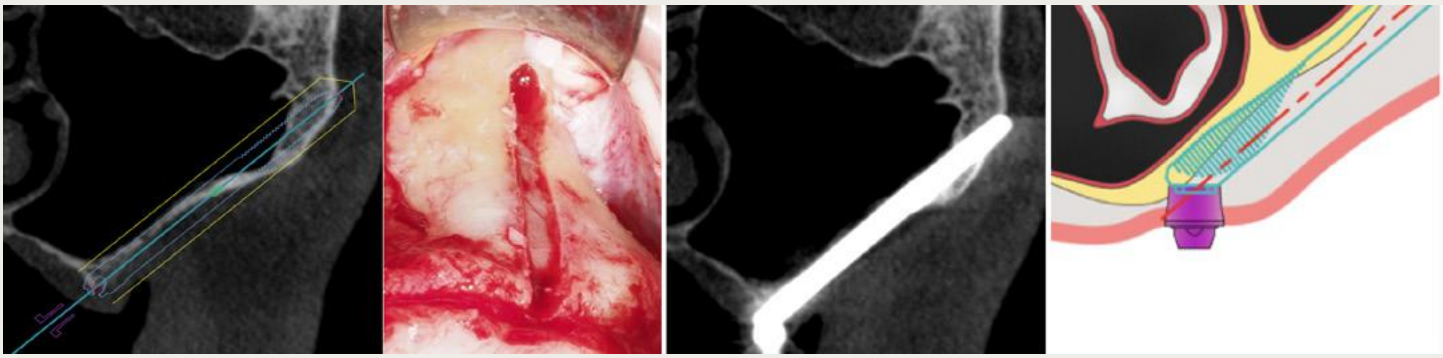

Fig. 2: If residual bone architecture is inadequate at the crestal level, the coronal osteotomy was buccally shifted to prevent future sinus or nasal-oral communication/fistula. This osteotomy type was named 'channel osteotomy.'

Fig. 3a: OPG showing a terminal dentition.

Fig. 3b: Occlusal clinical view of the four ZAGA zygomatic implants. The anterior has a cylindrical section (ZAGA Round), whereas the posterior presents an arc of circumference section (ZAGA Flat). Note the precise type of osteotomy. No 'window' or 'slot' was performed before the implant placement. BIC is optimized. The sinus membrane is respected. Soft tissue vascularity is not compromised.

Fig. 3c: OPG showing the immediate prostheses retained by the quadruple installation of zygomatic implants.

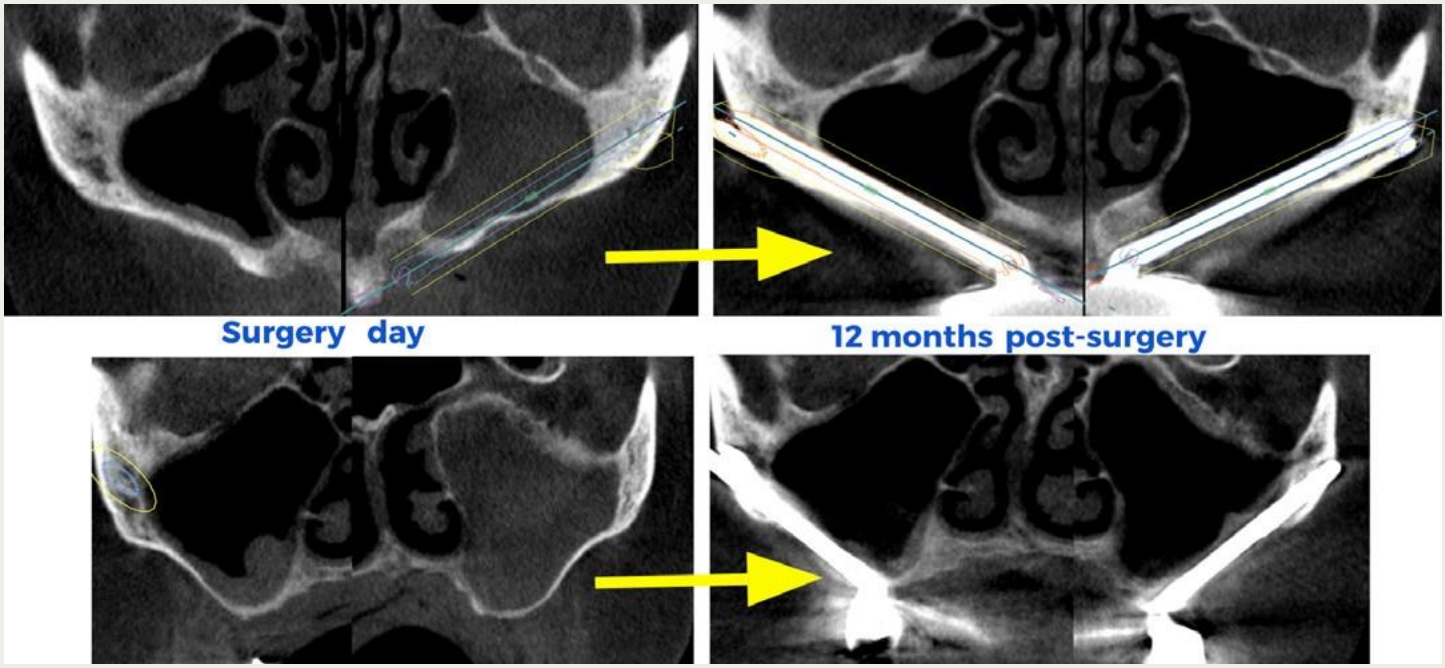

Fig. 4: The pre-surgery CBCT cuts of the planned sites show sinus occupation and several bony defects produced by previous failed grafting and implants. The transparent one-year post-surgery CBCT cuts indicate an excellent response to the used ZAGA surgical protocol in combination with ZAGA zygomatic implants.

When adopting the ZAGA concept, an implant path can be intra-sinus, extra-sinus (Fig. 3a, b, c), or involve multiple intermediary positions using the maxillary wall as an additional source of anchorage. Once the anatomic features of that specific patient have been visualized and studied, the ZAGA concept provides the surgeon with a customized protocol for decision-making before performing a zygomatic osteotomy[6]. After that, a site-specific 'round' or 'flat' zygomatic implant section should be selected to optimize results.

The strict ORIS criteria[5,7] have been used to evaluate the combination of the ZAGA concept, with the new ZAGA implant designs capable of adapting to a patient's anatomy. Results consistently show less traumatic osteotomy, better implant stability, bone-to-implant contact, and improved bone sealing around the implant neck. Additionally, the rate of late sinus complications dramatically decreases, culminating in successful long-term clinical outcomes[8] (Fig. 4).

References

1. Aparicio C. A proposed classification for zygomatic implant patients based on the Zygoma Anatomy-Guided Approach (ZAGA): A cross-sectional survey. Eur J Oral Implantol 2011
2. Aparicio C (ed) Zygomatic Implants: The Anatomy-Guided Approach, ed 1. Chicago: Quintessence, 2012.
3. Aparicio C, Polido W, Zarrinkelk H. The Zygoma Anatomy-Guided Approach for Placement of Zygomatic Implants. Atlas Oral Maxillofacial-Surg Clin-N-Am – 2021
4. Aparicio C, et al. Extra-sinus zygomatic implants: Three-year experience. Clin Implant Dent Relat Res 2010 (E-pub 2008)
5. Aparicio C, Manresa C, Francisco K, et al. Zygomatic implants placed using the zygomatic anatomy-guided approach versus the classical technique. Clin Implant Dent Relat Res 2014
6. Aparicio et al. Identification of the Pathway and Appropriate Use of Four Zygomatic Implants in the Atrophic Maxilla JOMI 2021
7. Aparicio C, López-Piriz R, Albrektsson T. ORIS criteria of success for the zygoma-related rehabilitation. JOMI 2020
8. Aparicio C, Polido WD, Chow J, Davo R, Al-Nawas B. Round and Flat Zygomatic Implants: A 1 Year follow-up Non-Interventional Study. Int J of Implant Dent. 2021 Submitted.

Implant and laser dentistry: The past, the present and the future

By Navid Rahmani, DDS, Former Academy News *Editorial Consultant and Guest Contributor*

In the past, implant and laser dentistry represented two parallel universes with little overlap. Now, as we look for solutions for peri-implantitis, both laser and implant clinicians are starting to wonder if they should be on the same wavelength.

Based on current evidence in the literature, lasers have already been shown to have some useful applications in implant dentistry. As laser applications are refined over time, and with more research, lasers are expected to have more applications involving implant dentistry. Your future as an implant clinician will probably involve lasers and your next big investment may be in laser technology.

The purpose of this article is to share my experiences plunging into the laser world. I hope that I can provide you with some helpful insights. As I looked at the scientific research behind lasers, I realized that compared to implant dentistry, laser dentistry research is significantly deficient. It seems that the dental laser world needed a Prof. **Per-Ingvar Brånemark** and a truly independent multi-disciplinary evidence-based organization like AO a long time ago to create a scientific foundation based on well-defined protocols.

Laser dentistry is strongly influenced by manufacturers, and there are many clinicians wearing the team uniform of their favorite brand. As a result, the field of laser dentistry has been polarized, distorting the focus needed by novice students to learn the basics while filtering out various corporate agendas. Knowing what is science and what is hype in laser dentistry is even more challenging because understanding lasers is sophisticated. It requires acquiring and updating your knowledge in physics, chemistry, biology (histology), and wound healing while navigating around the land mines and traps set in place in the laser dentistry landscape by some with special agendas in the corporate world.

Over the years, I've purchased several lasers for my periodontal practice. As a relatively earlier adopter of laser technology, I found my initial experience with the first lasers that I purchased were somewhat disappointing. I wasn't able to use them for the outcomes that were advertised. What was missing was evidence-based, well-defined laser protocols with the strict parameters needed to achieve predictable outcomes. However, I didn't give up and continued educating myself. With education and experience, I was able to find more and more uses for my laser practice until it became an integral part of my practice.

In more recent years, I purchased a different laser and I've noticed a tremendous improvement in availability of laser education based on more evidence-based protocols. I see this as a sign that the dental laser field is becoming more science based which will guarantee it a larger role in dental practice in the future. My prediction and advice for implant clinicians, researchers and organizations who aren't involved with lasers is to start learning more about lasers as it's likely that it will become a more significant part of implant dentistry in the future.

References

1. Romanos G. Current concepts in the use of lasers in periodontal and implant dentistry. J Indian Soc Periodontol. 2015 Sep-Oct;19(5):490-4.
2. Lin GH, Suárez López Del Amo F, Wang HL. Laser therapy for treatment of peri-implant mucositis and peri-implantitis: An American Academy of Periodontology best evidence review. J Periodontol. 2018 Jul;89(7):766-782.
3. Wang, CW, Ashnagar, S, Di Gianfilippo, R, Arnett, M, Kinney, J, Wang, HL. Laser-assisted regenerative surgical therapy for peri-implantitis: A randomized controlled clinical trial. J Periodontol. 2021; 92: 378–388.

Back to the future of osseointegration

By Mehrdad Favagehi, DDS, MS, Academy News *Editor*

Dr. Mehrdad Favagehi

In accord with the theme of the 2022 AO Annual Meeting, "Honor the Past, Treasure the Present, Shape the Future," the goal of the current issue of AO *Academy News* was to look back in the rear view mirror as we buckle up for our journey forward toward a successful future in osseointegration.

The first AO Annual Meeting I attended was in Palm Springs, California in 1999. It was like watching the movie, "Back to the Future," where I saw glimpses of my own future career in implant dentistry.

To refresh my memory, I recently watched a DVD of the 1999 AO Annual Meeting. The meeting theme was the "Biotechnology Revolution" with a focus on tissue engineering. Over twenty years later, as we travel back to Southern California for another AO meeting, Dr. **James Gurley**, the chair of the Research Submissions Committee reports that tissue engineering is the number one topic among the 2021 submissions.

During the 1999 meeting, Prof. **Per-Ingvar Brånemark** introduced zygoma implants to the dental profession as another chapter of his work in osseointegration. Since then, zygoma implants have become an integral part of implant dentistry and the article by Drs. **Carlos Aparicio** and **Yong-Han Koo** is a testament to that foresight.

The typical 1999 protocol to investigate full arch immediate loading included the placement of several extra reserve implants, as the investigators feared early implant failures. None were reported. Their work has set the stage for the "ultimate" in surgical and restorative implant dentistry: Immediate implant placement, immediate restoration in the aesthetic zone for single implants. Please see an example in the article by Dr. **Riad Almasri**.

> My friends, may you enjoy the consequences of your profession and as you look in to the future, consider that we're just in the beginning.
>
> — **Per-Ingvar Brånemark**

It's nice to achieve the "ultimate" in dental practice, but the "holy grail" in implant dentistry involves long-term success for 100% of implants. As we seek to achieve that goal, we need to eliminate peri-implantitis and so we should go back to the drawing table and re-examine everything we do and use under the microscope.

In his guest editorial, that's what Dr. **Daniel Buser** has done. He provides us a brilliant review of the past, present and future of various implant designs and surfaces over time. Interestingly, he seems to find the answer in a 1993 editorial by Dr. **Dennis P. Tarnow** who prophesized the Hybrid Design Implant (HDI) concept for the future of implant dentistry. Please see the article by Dr. Tarnow.

Sometimes to find the answers for the future, we have to look in the past. With this theme in mind, the 2022 Annual Meeting committee under the leadership of Dr. **German O. Gallucci** has set up an exceptional Annual Meeting line up that is designed to give us glimpses of our future in implant dentistry based on a historical perspective. You can attend the Annual Meeting both in person or virtually, sorry, we still don't know how to beam you up yet! But those in the Southwest can have their self-driving car get them there. I hope to see you in San Diego, as we thank our hard-working president Dr. **Tara L. Aghaloo** and welcome our new president, Dr. **Amerian D. Sones**.

The Editor's Editorial is intended to contribute to the dialogue on issues important to implant dentists. The views expressed in the editorial do not necessarily reflect the policy of the Academy of Osseointegration or its board of directors. To provide feedback about this edition, or to contribute as a guest author, please contact me at mfavagehi@yahoo.com. We will endeavor to publish pertinent comments or views when space permits.

Dentsply Sirona Implants The Best Just Got Better

Introducing DS PrimeTaper™

DS PrimeTaper is a demonstration of science and art in harmony. With immediate function and intuitive digital workflows, these unique implants will complement and enhance your artistry.

1 *EFFICIENT HANDLING*

Feels great in your fingers, and even better when you see the result.

2 *LASTING BONE CARE*

Immediate function gives confidence and a load off your mind.

3 *ENVIABLE ESTHETICS*

Patients will look great for years to come… and so will you.

4 *SEAMLESS WORKFLOW INTEGRATION*

We've simplified the treatment process, so you can stay in the zone without interruption.

Discover Dentsply Sirona Implants

Clinically shown to be the **#1** *implant system for marginal bone maintenance*.*

2022 ANNUAL MEETING

IMPLANT DENTISTRY FOR ALL: HONORING The Past · TREASURING The Present · SHAPING The Future

Feb. 24–26 San Diego, CA

Visit us at **Booth # 400**

Join us at our Corporate Forum:
Thursday, Feb. 24, 8:00 am – 12:00 pm
Room # 28ABC

Scan here

* Norton, MR, Astrom, M, The Influence of Implant Surface on Maintenance of Marginal Bone Levels for Three Premium Implant Brands: A Systematic Review and Meta-analysis. Int J Oral Maxillofac Implants 2020;35(6):1099-111

Dentsply Sirona | Healthy Practices. Healthy Smiles.